


Operative Anatomy of the Skull Base: 3D Exploration with a Highly Detailed Interactive Atlas

Ralf A. Kockro^{1,2} Eike Schwandt² Florian Ringel² Christian Valentin Eisenring¹ 
Wieslaw Lucjan Nowinski³

¹ Department of Neurosurgery, Hirslanden Hospital, Zürich, Switzerland

² Department of Neurosurgery, University of Mainz, Mainz, Germany

³ John Paul II Center for Virtual Anatomy and Surgical Simulation, University of Cardinal Stefan Wyszyński, Warsaw, Poland

Address for correspondence Ralf A. Kockro, MD, Department of Neurosurgery, Center for Microneurosurgery, Hirslanden Hospital, Witellikerstrasse 40, 8032 Zürich, Switzerland (e-mail: ralf.kockro@hirslanden.ch).

J Neurol Surg B Skull Base 2022;83(suppl S2):e298–e305.

Abstract

Objective We evaluated the usefulness of a three-dimensional (3D) interactive atlas to illustrate and teach surgical skull base anatomy in a clinical setting.

Study Design A highly detailed atlas of the adult human skull base was created from multiple high-resolution magnetic resonance imaging (MRI) and computed tomography (CT) scans of a healthy Caucasian male. It includes the parcellated and labeled bony skull base, intra- and extracranial vasculature, cranial nerves, cerebrum, cerebellum, and brainstem. We are reporting retrospectively on our experiences with employing the atlas for the simulation and teaching of neurosurgical approaches and concepts in a clinical setting.

Setting The study was conducted at the University Hospital Mainz, Germany, and Hirslanden Hospital, Zürich, Switzerland.

Participants Medical students and neurosurgical residents participated in this study.

Results Handling the layered graphical user interface of the atlas requires some training; however, navigating the detailed 3D content from intraoperative perspectives led to quick comprehension of anatomical relationships that are otherwise difficult to perceive. Students and residents appreciated the collaborative learning effect when working with the atlas on large projected screens and markedly improved their anatomical knowledge after interacting with the software.

Conclusion The skull base atlas provides an effective way to study essential surgical anatomy and to teach operative strategies in this complex region. Interactive 3D computer graphical environments are highly suitable for conveying complex anatomy and to train and review surgical concepts. They remain underutilized in clinical practice.

Keywords

- interactive 3D brain atlas
- operative anatomy
- human skull base
- neurosurgery training

Introduction

The structural anatomy of the skull base and adjacent structures is very complex. Surgery in this region can be challenging due to the density of functionally extremely important and at the same time fragile structures, such as cranial nerves, arterial and venous vasculature, the pituitary apparatus, the brainstem, the inner ear, and the orbits. Narrow corridors along or through

the skull base provide surgical access to this three-dimensional (3D) labyrinth and, when learning to become a skull base surgeon, one quickly realizes that understanding the anatomy is most essential. That is, not simply the anatomy as it is displayed in textbooks or as it can be identified in tomographic imaging. It is the anatomy as it is encountered intraoperatively while inspecting the surgical cavity and it is the structural configuration that needs to be anticipated beyond the visible

received

August 10, 2020

accepted

February 24, 2021

published online

June 3, 2021

© 2021, Thieme. All rights reserved.
Georg Thieme Verlag KG,
Rüdigerstraße 14,
70469 Stuttgart, Germany

DOI <https://doi.org/10.1055/s-0041-1729975>.
ISSN 2193-6331.

surface as tissue dissection or bone-work is performed. The endeavor of comprehending this anatomy is a multimodal process, traditionally based on the study of textbooks and the experience one gains while assisting experienced surgeons and, above all, dissecting cadaveric skull bases in dedicated courses. Repeated courses are necessary to gain confidence in dealing with this surgical region, and a large proportion of time and effort initially is expended in understanding and appreciating the basic 3D relationships of the structures along the various surgical routes. Additionally, cadaveric temporal bones are not easily available and carry with them the risk of transmission of infectious agents.¹

Over the past three decades, computational power, especially with respect to graphical rendering, has allowed generating and displaying 3D anatomy with increasing resolution, realism, and interactivity. Many research groups have developed 3D models of the skull base or parts thereof and it has been shown that these systems can effectively display and convey spatial 3D information and substantially improve the surgical training process.^{2–17}

Nowinski et al have been developing electronic atlases of the brain since the mid-1990s. The first 3D atlas¹⁸ was based on a digitized, enhanced, and extended model of the Schaltenbrand et al¹⁹ and the Talairach and Tournoux²⁰ atlases. It focused on deep brain structures and has been clinically used as a 3D map during functional stereotactic neurosurgery. The subsequent addition of highly detailed arterial and venous vasculature, cortex morphology, white matter tracts, and cranial nerves significantly expanded the atlas.^{21,22} The matrix for generating these structures was high-resolution magnetic resonance imaging (MRI) of a healthy Caucasian male (Wieslaw Nowinski). The most recent version of the atlas was developed from 2010 to 2015^{23,24} and contains the skull base. It includes accurate bone morphology, derived from computed tomography (CT) of the same male subject, cranial nerves, the structures of the inner ear, arterial and venous vasculature, and the brainstem with its major fiber tracts and nuclei. Emphasis has been placed on an interface enabling intuitive and effective 3D navigation within clearly labeled structures and tools for surgical viewpoint simulation and structural manipulation. The aim of this work was to evaluate this skull base atlas with respect to its effectiveness of teaching anatomy and neurosurgical concepts to undergraduate medical students and residents alike.

Materials and Methods

Atlas Creation

The virtual models of the skull, brain, brainstem, cranial nerves, intra- and extracranial vasculature, white matter tracts, and visual and auditory systems were developed from 3- and 7-T MRI and high-resolution CT scans of the same healthy Caucasian male. The technical details of the 3D atlas building have been addressed elsewhere,²⁴ including segmentation and parcellation of the tomographic data into individual structures, 3D surface modelling, color-coding, and naming based on *Terminologia Anatomica*,²⁵ as well as placement of the models in the Talairach stereotactic coordinate system.²⁰ The

structural anatomy was validated against domain knowledge from multiple perspectives and communities including neurosurgery, neuroanatomy, neuroradiology, and terminology.

Content and Interface

A free copy of the atlas^{23,26} is available at <http://www.thieme.com/nowinski>.

The user first needs to fill in a questionnaire, submit it to Thieme, and wait for permission to download the atlas. The atlas does not work on Apple computers.

The 3D skull base model contains five bones (frontal, paired temporal, occipital, sphenoid, and ethmoid), including the foramina and canals, blood vessels, and cranial nerves (CN) I–XII (bilateral with more than 600 segments) that pass in and out of the bones. The structures of the brain and brainstem, which have been developed for earlier versions of the atlas, are available within the same 3D workspace and can be switched on or off at any time.

A mouse- and keyboard-based interface offers a variety of functions for structure assembly and disassembly, real-time manipulation (zoom, rotate, pan, set views), 3D annotation, and quantification (readout of distances, vessel diameters, and stereotactic coordinates). Any configuration of bone, brain, brainstem, intra- and extracranial vessels, and cranial nerves may be composed. Navigation is supplemented with moveable axial, coronal, and sagittal 2D MRI image planes along with cut planes dissecting the 3D content in seven directions. All 3D objects are automatically labeled and allow for additional manual annotation. ► **Fig. 1** shows an overview of the virtual skull base, and parts of the brain, including the user interface.

Atlas Assessment

The atlas has been used since 2015 at the local Department of Neurosurgery at Hirslanden Hospital, Zürich, to aid discussion of anatomical spatial relationships while planning patient-specific surgical approaches with neurosurgical residents and fifth-year medical students during their clinical elective. Since 2016, working with the atlas has been part of biannually held clinical courses for fourth-year students of the Johannes Gutenberg University Medical School, Mainz, Germany. These students had completed their anatomy courses (cadaver dissection) in their second year and chose neurosurgery as a 1-week clinical elective as part of their mandatory surgery teaching curriculum. During this 1-week period, a group of eight students participated in daily clinical activities and visited the operating room as observers. The main neurosurgery topics were discussed with emphasis on the anatomy of the brain and skull base in the context of surgical approaches. Students and residents were encouraged to use the atlas independently rather than relying on having the anatomy of the atlas demonstrated to them. At the end of the sessions, all student and residents were questioned about their experiences with the software, especially with respect to spatial learning. The students of the courses in Mainz (48 in total) were additionally encouraged to summarize their thoughts in a short, written report. These

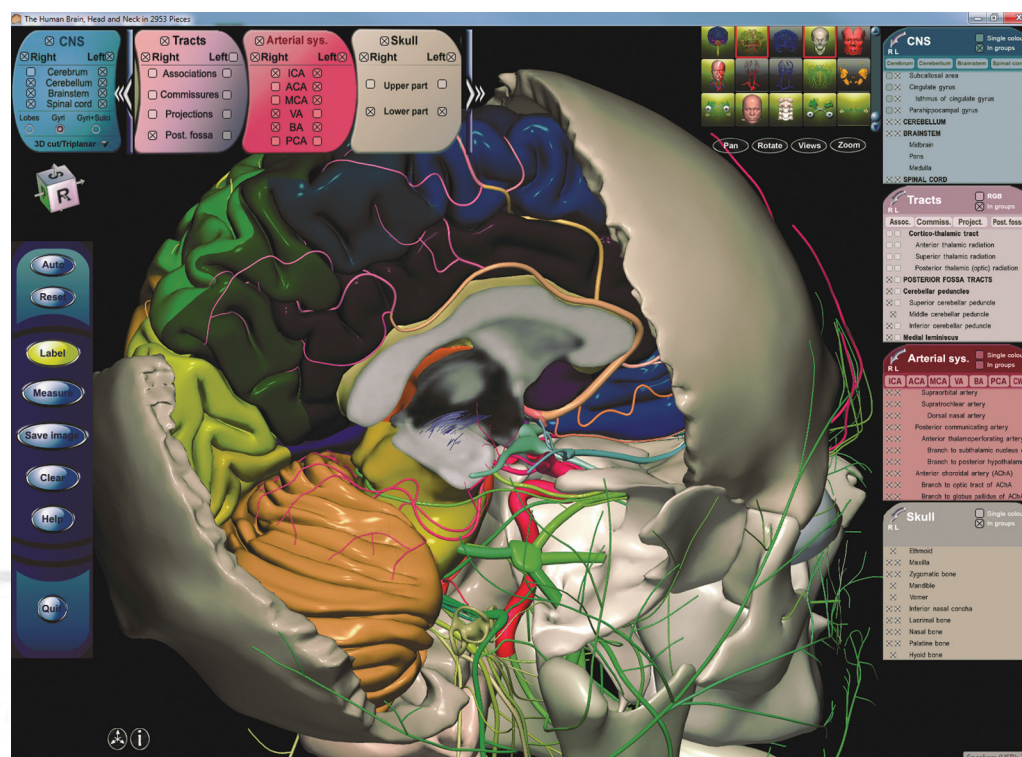


Fig. 1 Overview including user interface. The right temporal and parietal bones are switched off.

reports were assessed in a semistructured manner for common themes and observations.

Results

Atlas Content and Interface

Students and residents universally viewed the system positively. In their written reports (24 in total), most students reported working with the atlas as being a key experience in the process of understanding the spatial relationships of intracranial and skull base anatomy. Value was seen in the combination of theoretical information obtained from the atlas and the subsequent implementation of this knowledge during surgery, especially with regard to understanding the surgical trajectory, vasculature, and cranial nerves.

Most participants initially found the interface difficult to maneuver. As such, a 10-minute tutorial was introduced to overcome this initial challenge. It was found to be especially important to become familiar with the process of quickly switching on and off relevant structures to strike the right balance of structural density. During this process, it became evident that the display of fewer structures may allow for better spatial orientation and easier navigation toward and through them. Once having mastered the learning curve of handling the interface, the process of navigating toward and through structures along virtual surgical trajectories led to an intricate engagement with the virtual anatomy. Switching on and off structures, rotating, panning, and the process of zooming in and out toward target structures were the functions used most frequently to develop an appreciation of favorable surgical corridors.

Illustrative Cases

Atlas-based illustrations of surgical approaches are presented in ►Figs. 2–5.

Three videos were recorded while working with the atlas. They have not been cut or edited in any way to demonstrate

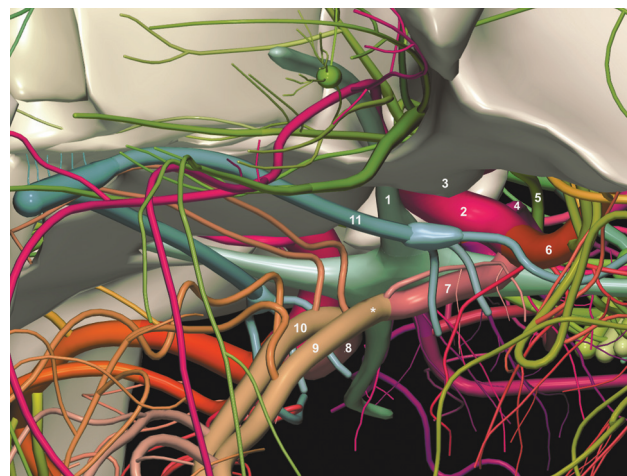


Fig. 2 Subfrontal/pterygoid view illustrating the relationships of important structures encountered: right optic nerve (1), right ICA (internal carotid artery) (2), emerging lateral to the optic nerve, being partially hidden by the right anterior clinoid process (3), the branching of the posterior communicating artery (4), the course of the oculomotor nerve (5), the bifurcation of the ICA into the MCA (middle cerebral artery) (6) and A1 segment of the ACA (anterior cerebral artery, 7). Note also the position of the contralateral A2 segment (8) and the two A2 segments of the ACA (9, 10). The anterior communicating artery would become visible when rotating toward a more anterior viewpoint; in this image, it is positioned behind the proximal A2 segment (*). The position of the olfactory bulb (11) is important to understand with respect to subfrontal dissection and retraction.

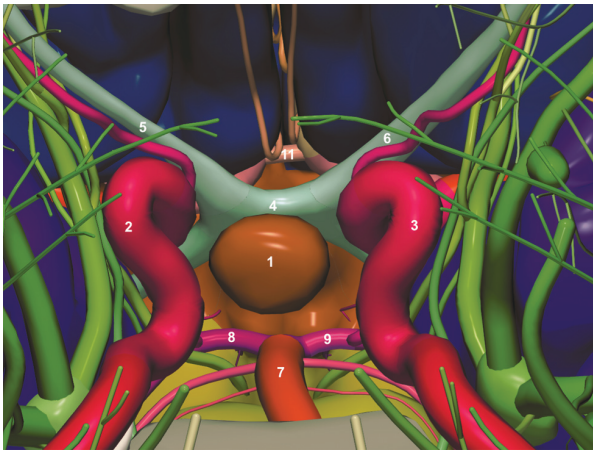


Fig. 3 Inferior view toward the pituitary gland, simulating a transsphenoidal approach. The bone is removed, clarifying the structures beyond it: pituitary gland (1), right and left ICA (internal carotid artery, 2,3) and cranial nerves III, IV, V1, and VI in the cavernous sinus lateral to it, optic chiasm (4) and right and left optic nerve (5,6). In the case of posterior extension of the approach, note the position of the basilar artery (7) and the right and left PCA (posterior cerebral artery, 8, 9). Also note the position of the anterior communicating artery (11), and the neighboring A1 and A2 segments, theoretically of relevance during tumor resection via a frontally extended, transsphenoidal approach.

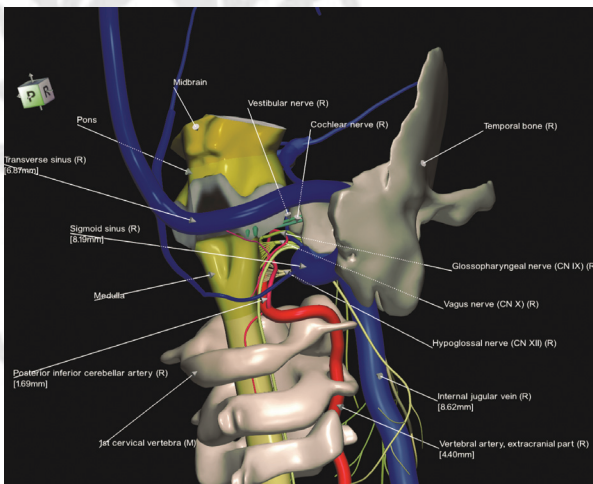


Fig. 5 Overview from posterolateral of the posterior fossa, brainstem, and upper cervical spine. The labels shown here were auto-generated by the software.

the interactivity and three-dimensionality of the atlas.

► **Video 1** shows an overview, ► **Video 2** a subfrontal and ► **Video 3** a retrosigmoid approach.

Video 1

Overview of the cranial base with the 3D interactive atlas. Osseous structures, cerebral vasculature, cranial nerves, the brainstem, and other anatomical structures may be explored with an interactive console. Online content including video sequences viewable at: <https://www.thieme-connect.com/products/ejournals/html/10.1055/s-0041-1729975>

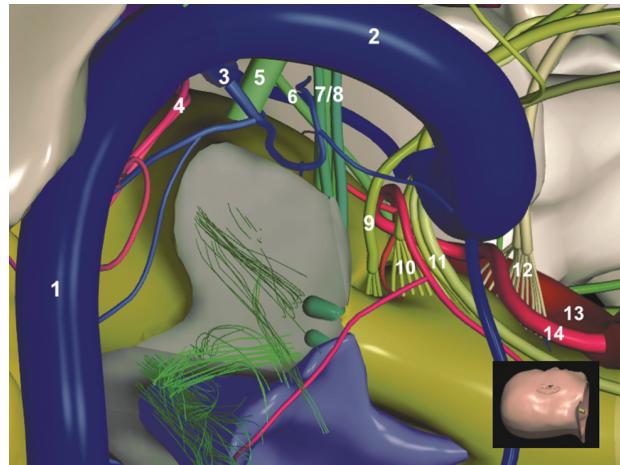


Fig. 4 Right retrosigmoid approach; the cerebellum has been removed (brachium pontis in gray). Overview of the brainstem, cranial nerves, and vasculature: transverse sinus (1), sigmoid sinus (2), superior petrosal vein (3), superior cerebellar artery (4), trigeminal nerve (5), abducens nerve (6), vestibular and cochlear nerve (7, 8), glossopharyngeal nerve (9), vagus nerve (10), accessory nerve (cranial and spinal component, 11), hypoglossal nerve (12), right vertebral artery (13), and right PICA (posterior inferior cerebellar artery, 14). Looking at the superior cerebellar artery (4), it can be understood that further caudal elongation can cause a conflict with the trigeminal nerve. The anatomy during microvascular decompression, taking into account the superior petrosal vein (Dandy's vein), can be illustrated. Note the position and course of the cranial nerves and arteries in the cerebellopontine angle and premedullary, relevant during tumor or aneurysm surgery.

Video 2

Virtual planning of a subfrontal approach with head positioning and simulation of the intraoperative corridor toward the cranial base including vasculature, optic chiasm, cranial nerves, and pituitary stalk. Online content including video sequences viewable at: <https://www.thieme-connect.com/products/ejournals/html/10.1055/s-0041-1729975>

Video 3

Virtual planning of a right retrosigmoid approach including head positioning and view toward the cerebellopontine angle with all cranial nerves and relevant vasculature. Online content including video sequences viewable at: <https://www.thieme-connect.com/products/ejournals/html/10.1055/s-0041-1729975>

Discussion

The bony- and soft-tissue components of the human skull base form a 3D space of overwhelming anatomical intricacy. Mastering the art of skull base surgery is an extensive process

continuously centered upon understanding the surgical target structures and the corridors that lead toward them. Traditionally, skull base anatomy has been taught by the use of drawings and pictures. Textbooks of anatomy,²⁷ neuroanatomy,^{28,29} neuroradiology,³⁰ and neurosurgery serve as a rich source for anatomical overview and some print atlases even provide 3D illustrations, which may be viewed with red–green glasses.³¹ Surgical approaches and concepts to the skull base have been the subject of several textbooks. *Atlas of Skull Base Surgery and Neurotology* by Jackler and Gralapp³² provides step-by-step descriptions of surgical techniques on the basis of detailed artistic drawings. *Skull Base Surgery*³³ by Janecka and Tiedemann illustrates surgical approaches with drawings and photographs of plastinated models as well as MRI and CT cross sections. In addition to drawings, several groups have published textbooks that include photographs of cadaver dissections: *Skull Base and Related Structures: Atlas of Clinical Anatomy*³⁴ by Lang, *Photo Atlas of Skull Base Dissection*³⁵ by Wanibuchi et al, and *Atlas of Surgical Approaches to Paranasal Sinuses and the Skull Base*³⁶ by Fliss and Gil comprise high-quality photographs as encountered through the most common skull base microscopic and endoscopic approaches.

Outstanding work has been done by the late Albert Rhoton Jr and his group, who have produced an excellent 3D schematic and cadaveric atlas of the brain and skull base accompanied by detailed explanations of surgical approaches.^{37–43} These contributions have advanced not only skull base surgery but also cranial microsurgery as a whole and were also employed in the modelling and verification of the atlas evaluated herein.

A limitation of anatomic textbook drawings and photographs is that it requires considerable mental effort to transform the illustrations into 3D constructs that reflect surgical viewpoints.

Working with 3D plastic models that are generated by stereolithography provides a fairly realistic appreciation of structural anatomy enhanced by tactile feedback while drilling.⁴⁴ The models, however, lack detail as it is difficult to manufacture minute structures such as cranial nerves and vasculature with current 3D printing technology, particularly when structures are suspended in space. Furthermore, subjecting these models to physical manipulation such as drilling would require mass production to target larger groups.

Computational power, especially with respect to graphical rendering, has allowed generating and displaying 3D anatomy with increasing resolution, realism, and interactivity,² and the complex structure of the skull base has seen it becoming the focus of these electronic atlases.

The data of the Visible Human Project, an endeavor of the National Library of Medicine to create a complete 3D representation of the male and female human body, comprising photographs of axial cadaver transection as well as corresponding CT and MRI image series, served as the basis for several anatomy visualization projects.^{11,45,46} Other anatomy atlases have been created based on a variety of tomographic imaging sources, which were integrated into a 3D model by employing 3D graphical drawing tools.^{47–49}

Specifically, with respect to skull base surgery, several research groups have developed 3D computerized models with 2D/3D interfaces to illustrate and help overcome visuospatial challenges. Recently, Hendricks et al presented a highly detailed and graphically appealing virtual model of the human skull.³ Kimura et al⁵⁰ and Shono et al⁵¹ present simulation systems for aneurysm surgery, Heiland et al⁵² focused on maxillary and dental surgery, and de Notaris et al^{8,9} used 3D simulation techniques to illustrate general concepts of skull base surgery, focusing on anterior approaches. The anatomy of the temporal bone and transpetrous approaches has been the focus of several research groups, largely due to the exceptional complexity of this region.^{4,5,7,15} Bernardo et al described an interactive virtual temporal bone dissection model based on stereoscopically rendered photographs from sequentially deeper cadaveric dissections.⁷ The user was able to erase parts of the layers of images with a mouse cursor and hence experience the impression of drilling this complex terrain during a surgical approach.

The concept of combining 3D computer graphics with a 3D interface and a stereoscopic display resulted in the development of the virtual reality system Dextroscope. It has been developed to plan and simulate neurosurgery with patient-specific imaging data, and since it contains virtual bone drilling tools, it proved to be especially useful for skull base surgery. The system has been used for planning of more than 2,000 cases^{6,12–14,17,53} in different institutions and has been evaluated with questionnaires¹⁷ and with respect to clinical outcome after being used for aneurysm surgery planning.⁵³

When simulating skull base surgery with 3D *patient-specific* imaging data, the 3D segmentation and display of minute structures is often challenging. Cranial nerves or smaller vasculature, especially when distorted by tumors, may be difficult to identify in preoperative MRI and hence the patient-specific 3D model lacks detail. We have therefore sought to develop a detailed model of the temporal bone based on the photographic Visible Human data and embed it in the Dextroscope. It contains all cranial nerves and the arterial and venous vasculature and its space exploration and virtual drilling tools allow simulating key approaches through and along the area of the temporal bone and the middle and posterior fossa.¹⁵

We have been using the current atlas to teach medical students and neurosurgical trainees. Displaying the atlas with a projector on a large screen creates a collaborative scenario enabling clear and unambiguous depiction of the three-dimensionality of structures and an interactive forum for discussing surgical strategies. Reports from nonmedical fields, such as geophysical exploration, engineering, and architecture, show that computer-generated 3D scenarios add value in understanding spatial relationships and in discussing specific 3D tasks.⁵⁴ Our experiences confirm this observation. When using the atlas, a precise framework is set to discuss surgical anatomy, and the simulation of intraoperative viewpoints provides unambiguous information about spatial facts. While navigating along surgical corridors, for instance, subfrontal, subtemporal, or retromastoid, the structures within reach as

well as those to be avoided can clearly be demonstrated (see ►Figs. 2–5). The accessibility of certain parts of the vasculature while dealing with, for example, aneurysms or microvascular decompression surgery can be understood in view of the neighboring cranial nerves and the skull base. The most striking difference to textbooks is the ability to shift viewpoints to instantly reveal different trajectories and distances toward relevant structures.

The level of detail and realism of the atlas renders it to be of primary benefit for students or junior residents. The main goal is to facilitate the transition of understanding of neuroanatomy as it is taught in anatomy classes to neurosurgical anatomy as it is encountered in the operating room. We observed that the students benefitted from grasping relatively simple anatomical spatial relationships, which are routine knowledge for experienced surgeons. A good example is viewing the “upside-down” anatomy of a subfrontal/pterional approach and the understanding that the carotid artery lies lateral to the optic nerve and then curves “downward” to form the A-complex, “below” and in front of the optic chiasm. Although we did not formally assess knowledge improvement, feedback during the anatomical discussions, and especially after observing live surgeries subsequent to atlas-based explorations, leads us to conclude that the students draw remarkable benefit from the teaching sessions with the atlas, confirming our earlier observations. In 2014, we assessed teaching the anatomy of the third ventricle by randomizing 4th year medical students to teach with standard 2D images or a 3D computer graphical model, with the latter perceived by students as superior to presentations of still images.⁵⁵

Other studies assessing small-group anatomy teaching with 3D technological support confirm that individual spatial ability is a predictor of improved learning outcomes.^{56–58}

From a neurosurgical perspective, the current atlas can be viewed as an interactive viewing space for essential structures, but not as a true neurosurgical simulator. It lacks predefined surgical approaches, variants, and simulated pathology, and it is limited by the fact that there is no free-hand craniotomy or drilling tool. However, since the virtual skull is parcellated along suture lines, removing individual skull bones may simulate surgical access to a certain degree. In addition, the ability to assemble and disassemble any region of the skull base and to cut it in axial, coronal, and sagittal planes allows a comprehensive insight into detailed bony skull base anatomy including its foramina, fissures, and embedded and adjacent cranial nerves and vessels. We therefore agree with Hendricks et al that a detailed and parcellated virtual human skull, even one lacking surgical simulation features such as drilling, is “a valuable resource for educational, research, and clinical endeavours.”³

Future directions will focus on extending the current anatomic model. Adding the tentorium and the skull base dura will result in a more realistic simulation of the intraoperative experience, for example, with respect to the architecture of skull base venous sinuses and the dural entry points of cranial nerves. Moreover, we plan to add skull variants and pathologies, as well as the optional display of

predefined surgical approaches. This advanced 3D model may be merged with immersive 3D content navigation—along the philosophy of 3D interaction provided by the Dextroscope. This will enable intuitive simulation of craniotomies and microscopic or endoscopic views along individually tailored surgical corridors. The integration of deformable models and haptic feedback would be the ultimate step toward a close-to-reality simulator, which could be a valuable tool for residents or attendings when preparing for certain surgical procedures.

An important question worth bearing in mind when developing such a platform is: what level of structural detail and realism is necessary for teaching? We believe that the illustration of neurosurgical concepts to students and junior residents does not require simulation that is on par with surgical realism. It should rather facilitate the spatial learning process by accurately displaying key anatomical structures and, above all, permit quick and intuitive interaction with these structures. The simulation of full microsurgical procedures remains limited by currently insurmountable obstacles such as realistic tissue dissection, control of bleeding, defining tumor borders, or maneuvering instruments within the constraints of a surgical corridor. With the currently available computer graphics and haptic simulation technology, these tasks cannot be simulated realistically and hence, for the time being, the ideal neurosurgical simulator must integrate a reasonable balance of computer graphical realism, complexity of interaction, and system performance.

Conclusion

This 3D atlas is a comprehensive source of 3D anatomy, embedded in a multifunctional user interface. It enables the viewing of essential structures from different microsurgical viewpoints and can help diminish the anatomical learning curve associated with skull base surgery. Given the limitations on junior surgeons' working hours and ever fewer opportunities to learn surgical anatomy in the operating room, computer-assisted 3D anatomical learning has a role to play in supplementing more traditional methods at all levels of training.

Informed Consent

Additional informed consent was obtained from all individual participants for whom identifying information is included in this article.

Ethical Approval

All procedures performed in studies involving human participants were in accordance with the ethical standards of the institutional and/or national research committee and with the 1964 Helsinki Declaration and its later amendments or comparable ethical standards. For this type of study, formal consent is not required.

Ethics

The manuscript does not contain clinical studies or patient data.

Funding

None.

Conflict of Interest

All authors certify that they have no affiliations with or involvement in any organization or entity with any financial interest (such as honoraria; educational grants; participation in speakers' bureaus; membership, employment, consultancies, stock ownership, or other equity interest; and expert testimony or patent-licensing arrangements) or nonfinancial interest (such as personal or professional relationships, affiliations, knowledge, or beliefs) in the subject matter or materials discussed in this manuscript.

References

- 1 Michaels L, Soucek S, Liang J. The ear in the acquired immunodeficiency syndrome: I. Temporal bone histopathologic study. *Am J Otol* 1994;15(04):515–522
- 2 de Faria JWV, Teixeira MJ, de Moura Sousa Júnior L, Otoch JP, Figueiredo EG. Virtual and stereoscopic anatomy: when virtual reality meets medical education. *J Neurosurg* 2016;125(05):1105–1111
- 3 Hendricks BK, Patel AJ, Hartman J, Seifert MF, Cohen-Gadol A. Operative anatomy of the human skull: a virtual reality expedition. *Oper Neurosurg (Hagerstown)* 2018;15(04):368–377
- 4 Koppersmith RB, Johnston R, Moreau D, Loftin RB, Jenkins H. Building a virtual reality temporal bone dissection simulator. *Stud Health Technol Inform* 1997;39:180–186
- 5 Stredney D, Wiet GJ, Bryan J, et al. Temporal bone dissection simulation—an update. *Stud Health Technol Inform* 2002;85:507–513
- 6 Hwang P, Kockro R, Lee C. Virtual reality simulation for skull base surgery. *Asian J Neurosurg* 2007;1:1–8
- 7 Bernardo A, Preul MC, Zabramski JM, Spetzler RF. A three-dimensional interactive virtual dissection model to simulate transpetrous surgical avenues. *Neurosurgery* 2003;52(03):499–505, discussion 504–505
- 8 de Notaris M, Prats-Galino A, Cavallo LM, et al. Preliminary experience with a new three-dimensional computer-based model for the study and the analysis of skull base approaches. *Childs Nerv Syst* 2010;26(05):621–626
- 9 de Notaris M, Palma K, Serra L, et al. A three-dimensional computer-based perspective of the skull base. *World Neurosurg* 2014;82(6, Suppl):S41–S48
- 10 Estevez ME, Lindgren KA, Bergethon PR. A novel three-dimensional tool for teaching human neuroanatomy. *Anat Sci Educ* 2010;3(06):309–317
- 11 Höhne K-H. *VOXEL-MAN 3D-Navigator: Brain and Skull: Regional, Functional, and Radiological Anatomy [CD-ROM]*. Version 2.0. Heidelberg: Springer; 2001
- 12 Kockro RA, Serra L, Tsai YT, et al. Planning of skull base surgery in the virtual workbench: clinical experiences. *Stud Health Technol Inform* 1999;62:187–188
- 13 Kockro RA, Serra L, Tseng-Tsai Y, et al. Planning and simulation of neurosurgery in a virtual reality environment. *Neurosurgery* 2000;46(01):118–135, discussion 135–137
- 14 Kockro RA, Stadie A, Schwandt E, et al. A collaborative virtual reality environment for neurosurgical planning and training. *Neurosurgery* 2007;61(05, Suppl 2):379–391, discussion 391
- 15 Kockro RA, Hwang PY. Virtual temporal bone: an interactive 3-dimensional learning aid for cranial base surgery. *Neurosurgery* 2009;64(05, Suppl 2):216–229, discussion 229–230
- 16 Oishi M, Fukuda M, Yajima N, et al. Interactive presurgical simulation applying advanced 3D imaging and modeling techniques for skull base and deep tumors. *J Neurosurg* 2013;119(01):94–105
- 17 Stadie AT, Kockro RA, Reisch R, et al. Virtual reality system for planning minimally invasive neurosurgery. Technical note. *J Neurosurg* 2008;108(02):382–394
- 18 Nowinski W, Bryan R, Raghavan R. *The Electronic Clinical Brain Atlas: Multiplanar Navigation of the Human Brain [CD-ROM]*. New York, NY: Thieme; 1997
- 19 Schaltenbrand G, Wahren W, Hassler RG. *Atlas for Stereotaxy of the Human Brain*. Stuttgart: Thieme; 1977
- 20 Talairach J, Tournoux P. *Co-planar Stereotaxic Atlas of the Human Brain: 3-Dimensional Proportional System: an Approach to Cerebral Imaging*. Stuttgart-New York: Thieme; 1988
- 21 Nowinski WL, Chua BC, Yang GL, Qian GY. Three-dimensional interactive and stereotactic human brain atlas of white matter tracts. *Neuroinformatics* 2012;10(01):33–55
- 22 Nowinski WL, Johnson A, Chua BC, Nowinska NG. Three-dimensional interactive and stereotactic atlas of cranial nerves and nuclei correlated with surface neuroanatomy, vasculature and magnetic resonance imaging. *J Neurosci Meth* 2012;206(02):205–216
- 23 Nowinski WL. 3D atlas of the brain, head and neck in 2953 pieces. *Neuroinformatics* 2017;15(04):395–400
- 24 Nowinski WL, Thauung TSL. A 3D stereotactic atlas of the adult human skull base. *Brain Inform* 2018;5(02):1
- 25 Federative Committee on Anatomical Terminology (FCAT) *Terminologia Anatomica*. Stuttgart: Georg Thieme Verlag; 1998
- 26 Nowinski WLCB, Thauung TSL, Wut Yi SH. Human brain, head and neck in 2953 pieces. Available at: <http://www.thieme.com/nowinski/>
- 27 Gray H, Standring S. *Gray's Anatomy: The Anatomical Basis of Clinical Practice*. London: Churchill Livingstone; 2008
- 28 Lamperti ED, Ross LM, Schumacher U, Schulte E, Schuenke M. *Compr Head and Neuroanatomy (THIEME Atlas of Anatomy)*. | Edward D Lamperti. Head and Neuroanatomy (THIEME Atlas of Anatomy). 2010
- 29 Schuenke MSE, Schumacher U. *Atlas of anatomy. Head and neuroanatomy*. Stuttgart-New York: Thieme; 2010
- 30 Harnsberger H, Osborn A, MacDonald A, et al. Diagnostic and surgical imaging anatomy: brain, head & neck, spine. *AJNR Am J Neuroradiol* 2007;28(04):795–796
- 31 Hirsch MC, Kramer T. *Neuroanatomy: 3D-Stereoscopic Atlas of the Human Brain*. Berlin: Springer Science + Business Media; 2012
- 32 Jackler RK, Gralapp C. *Atlas of Skull Base Surgery and Neurotology*. New York, NY: Thieme; 2009
- 33 Janecka IP, Tiedemann K. *Skull Base Surgery: Anatomy, Biology, and Technology*. Philadelphia, PA: Lippincott-Raven; 1997
- 34 Lang J. *Skull Base and Related Structures: Atlas of Clinical Anatomy*. Stuttgart: Schattauer Verlag; 2001
- 35 Wanibuchi M, Friedman AH, Fukushima T. *Photo Atlas of Skull Base Dissection: Techniques and Operative Approaches*. New York, NY: Thieme; 2009
- 36 Fliss DM, Gil Z. *Atlas of Surgical Approaches to Paranasal Sinuses and the Skull Base*. Berlin: Springer; 2016
- 37 Rhoton AL Jr. Jugular foramen. *Neurosurgery* 2000;47(3, Suppl):S267–S285
- 38 Rhoton AL Jr. The foramen magnum. *Neurosurgery* 2000;47(3, Suppl):S155–S193
- 39 Rhoton AL Jr. The orbit. *Neurosurgery* 2002;51(4, Suppl):S303–S334
- 40 Rhoton AL Jr. The anterior and middle cranial base. *Neurosurgery* 2002;51(4, Suppl):S273–S302
- 41 Rhoton AL Jr. The sellar region. *Neurosurgery* 2002;51(4, Suppl):S335–S374
- 42 Rhoton AL Jr. *Rhoton Cranial Anatomy and Surgical Approaches*. Philadelphia, PA: Lippincott Williams & Wilkins; 2003

- 43 Rhoton Al Jr. The temporal bone and transtemporal approaches. *Neurosurgery* 2000;47(3 Suppl):S211–65
- 44 Stoker NG, Mankovich NJ, Valentino D. Stereolithographic models for surgical planning: preliminary report. *J Oral Maxillofac Surg* 1992;50(05):466–471
- 45 Ackerman MJ. The Visible Human Project: a resource for education. *Acad Med* 1999;74(06):667–670
- 46 Ackerman MJ, Yoo T, Jenkins D. From data to knowledge—the visible human project continues. *Stud Health Technol Inform* 2000;84(Pt 2):887–890
- 47 Berkovitz B. *Interactive Head and Neck* [CD]. London: Primal Pictures Limited; 2003
- 48 Jakab M, Kikinis R. *Head and Neck Atlas*. Boston, MA: Surgical Planning Laboratory Harvard Medical School; 2015
- 49 Visible Body® Human Anatomy Atlas 2019: Complete 3D Human Body. Boston, MA: Visible Body 2019
- 50 Kimura T, Morita A, Nishimura K, et al. Simulation of and training for cerebral aneurysm clipping with 3-dimensional models. *Neurosurgery* 2009;65(04):719–725, discussion 725–726
- 51 Shono N, Kin T, Nomura S, et al. Microsurgery simulator of cerebral aneurysm clipping with interactive cerebral deformation featuring a virtual arachnoid. *Oper Neurosurg (Hagerstown)* 2018;14(05):579–589
- 52 Heiland M, Von Sternberg-Gospos N, Pflesser B, et al. Virtual simulation of dental surgery using a three-dimensional computer model with a force feedback system [in German]. *Mund Kiefer Gesichtschir* 2004;8(03):163–166
- 53 Kockro RA, Killeen T, Ayyad A, et al. Aneurysm surgery with preoperative three-dimensional planning in a virtual reality environment: technique and outcome analysis. *World Neurosurg* 2016;96:489–499
- 54 Johnson A, Leigh J, Morin P, Van Keken P. GeoWall: stereoscopic visualization for geoscience research and education. *IEEE Comput Graph Appl* 2006;26(06):10–14
- 55 Kockro RA, Amaxopoulou C, Killeen T, et al. Stereoscopic neuroanatomy lectures using a three-dimensional virtual reality environment. *Ann Anat* 2015;201:91–98
- 56 Berney S, Bétrancourt M, Molinari G, Hoyek N. How spatial abilities and dynamic visualizations interplay when learning functional anatomy with 3D anatomical models. *Anat Sci Educ* 2015;8(05):452–462
- 57 Kirkman MA, Muirhead W, Nandi D, Sevdalis N. Development and psychometric evaluation of the “Neurosurgical Evaluation of Attitudes towards simulation Training” (NEAT) tool for use in neurosurgical education and training. *World Neurosurg* 2014;82(3–4):284–291
- 58 Yamine K, Violato C. A meta-analysis of the educational effectiveness of three-dimensional visualization technologies in teaching anatomy. *Anat Sci Educ* 2015;8(06):525–538



THIEME